NEFROLOGO IN CORSIA

Sagliker syndrome: first four cases in Bulgaria

R. Cholakova[1], **Petia Pechalova**[1], E. Kapon[2]

(1) Dipartimento di Chirurgia, Facoltà di Odontoiatria, Università Medica di Plovdiv, Bulgaria
(2) Unità di Dialisi, Ospedale Universitario "St. George", Plovdiv, Bulgaria

Testo tradotto dalla Dott.ssa Lucia Di Micco (Solofra, AV)

Corrispondenza a: Assoc. Prof. Petia F. Pechalova, DDS, MD, PhD; "Hr. Botev"3 Str. Plovdiv, Bulgaria; E-mail: pechalova@abv.bg

Abstract

Sagliker syndrome characterized with uglifying the appearance of the face due to secondary hyperparathyroidism in patients with chronic renal failure receiving dialysis long time ago.

The aim of the study was to identify any patients with Sagliker syndrome among the 78 patients receiving dialysis at the Dialysis ward, University Hospital "St. George", Plovdiv, Bulgaria.

Results: Four patients met the criteria for Sagliker syndrome: chronic renal insufficiency, secondary hyperparathyroidism, short stature, severe changes in the skull and jaw that lead to festoon-like uglifying face, dental abnormalities, "brown" tumors, deformations of the phalanges of the fingers, psychological diseases and depression.

Conclusion: The lack of control of the level of calcium and phosphorus in the blood in patients with chronic kidney disease leads to severe bone changes and psychological changes in patients with prolonged dialysis.

Key words: chronic renal failure, dialysis treatment, Sagliker syndrome, secondary hyperparathyroidism

Introduction

Sagliker syndrome was described in 2004. It represents the development of secondary hyperparathyroidism in patients with chronic renal failure. Improper treatment in the early stages of the disease is the cause of retention of phosphorus, vitamin D deficiency and disorder in the calcium-phosphorus metabolism. This leads to increased parathyroid hormone and development of secondary hyperparathyroidism. The commensurate increased serum alkaline phosphatase produces skeletal changes - renal rachitis, damage bone growth points in children, and subperiosteal changes in almost all bones. Affected patients have short stature, severe changes in the skull, deformities in upper and lower jaw, dental anomalies, "brown" tumors, severe psychological changes and depression [1] [2] [3] (full text) [4] [5] (full text) [6] [7] [8] [9] [10]. "Brown" tumors are bone lesions caused by rapid osteoclastic activity and peritrabecular sclerosis - result of hyperparathyroidism. In fact, they are not true neoplasia, but represent bone reparative process - fibrous-cystic osteitis. Radiographic characteristics of bone pathology in renal osteodystrophy are associated with demineralization, loss of lamina dura and trabecular bone, that looks like frosted glass [5] (full text) [11] (full text) [12]. The changes in the maxillofacial area are asymptomatic macrognathia

(localized or diffuse) with apparent pathological mobility of teeth in the affected region, abnormal occlusion, changes in the enamel and the pulp of teeth. The skeletal abnormalities affect elbow, collarbone, spine, long bones and small bones of the hands [6] [7] [8] [13]. Sagliker syndrome patients demonstrate very distinctive changes in the third phalanx of the fingers, which is curved upward.

The aim of this study was to identify any patients with Sagliker syndrome among the contingent of The dialysis ward at the University Hospital "St. George", Plovdiv, Bulgaria.

Materials and methods: We conducted a clinical examination and performed blood tests of all 78 patients receiving dialysis therapy more than one year (63 patients on hemodialysis, 15 – on peritoneal dialysis). Blood tests included a complete blood count, electrolyte *tests*, alkaline phosphatase and parathyroid hormone.

Based on the laboratory tests, eight of the patients were to a high degree of suspicion for renal osteodystrophy with parathormone values above 400 pg/ml. After comparing the results of clinical examination and laboratory tests, we found four patients who meet the criteria for Sagliker syndrome: chronic renal insufficiency, secondary hyperparathyroidism, short stature, severe changes in the skull and jaw that lead to festoon-likeuglifying face, dental abnormalities, "brown" tumors, deformations of the phalanges of the fingers, psychological diseases and depression.

Cases presentation

Case 1

27 years old male, who receives hemodialysis treatment for 12 years. Physical examination of the maxillo-facial area demonstrated maxillary and mandibular enlargement, especially

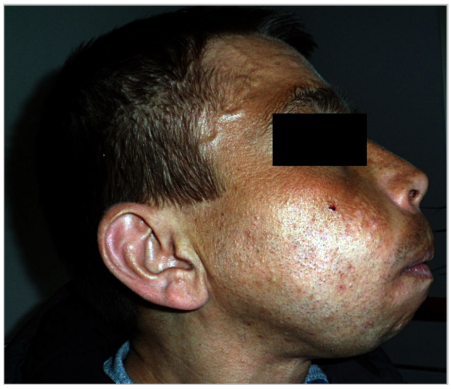

Figure 1.
Jaw enlargement

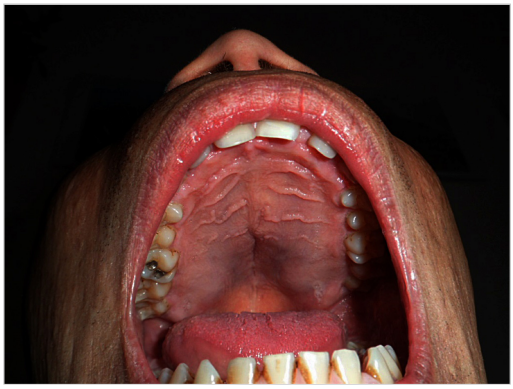

Figure 2.
Flat palate

in the anterior part (Figure 1), flat palate (Figure 2), increased sagittal size of the lower jaw, open bite, teeth displacement with tremas (Figure 3). We observed typical for patients with chronic renal failure, dark brown staining in the *cervical* area follows the gingival *festoon*, mostly on the lower teeth. The patient has short stature, narrow lateral and wide sagittal diameter of the chest (Figure 4), X - shaped lower limbs, with enlargement of the knee joint (Figure 5), upturned third phalanges of the hands. He was underwent a corrective surgery for the mandible enlargement seven years ago. Additionally, the patient was treated with Zemplar to suppress the effects of parathyroid hormone. Although the medication and surgery, jaws continue to grow up and deform.

Case 2

63 years old female, who receives hemodialysis treatment for 30 years. The physical examination of the maxillo-facial area demonstrated *totally toothless upper* and partialy *toothless* lower *jaws with slight mandibular prognathism*. The patient had previously received surgery

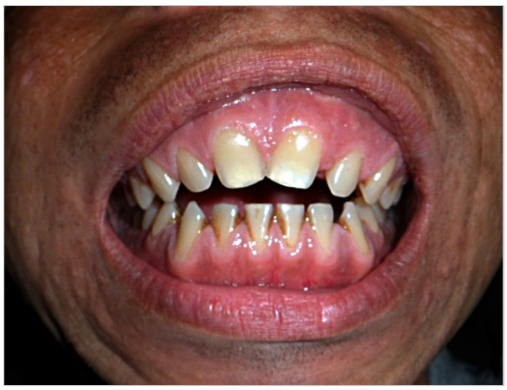

Figure 3.
Open bite with teeth displacement and tremas

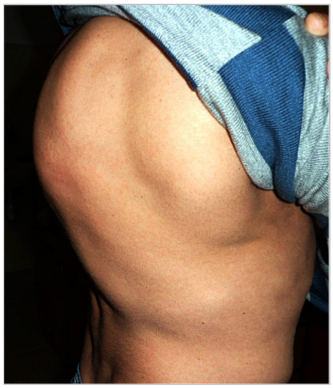

Figure 4.
Narrow lateral and wide sagittal diameter of the chest

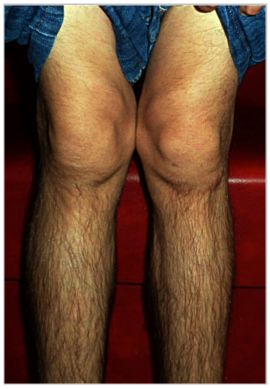

Figure 5.
X - shaped lower limbs, with enlargement of the knee joint

of the maxillary bone and was diagnosed with a "brown tumor". The patient has a short stature, X-shaped limbs, upturned nail phalanges (Figure 6), thickened ulna, deformed clavicle.

Case 3

63 years old female, who receives hemodialysis treatment for 6 years. The patient had partially toothless upper and lower jaws as a result of progressively increasing tooth mobility. Bone enlargement was observed especially in the anterior part of the maxilla and mandible as well as a deformed clavicle. The patient was treated with Zemplar.

Case 4

26 years old female, who receives hemodialysis treatment for 6 years. The physical examination demonstrated enlargement of the lower third of the face in the sagittal direction and deformation in the right infraorbital region. The patient had open bite, maxillary anterior teeth were inclined medially with tremas, the palate was flat with bone enlargement in the anterior area (Figure 7).

Results of the patients' paraclinical tests are shown in Table 1.

Discussion

Sagliker syndrome is a rare disease that occurs in patients with chronic renal failure on continuous hemodialysis in the absence of adequate control of the values of parathyroid hormone and alkaline phosphatase. This case series found that 6.34% of the patients developed Sagliker syndrome, which is much higher compared to other countries [6] [14] (full text). The increase of phosphorus in the blood and hypercalcemia, stimulate the release

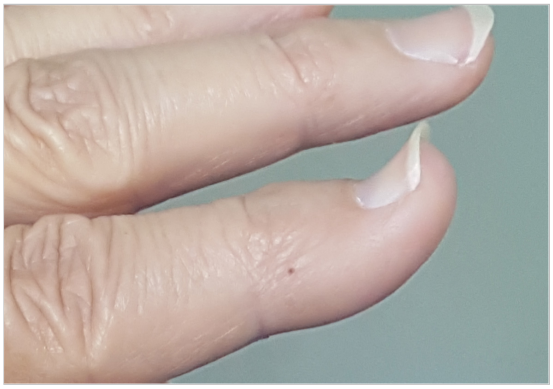

Figure 6.
Upturned nail phalanges

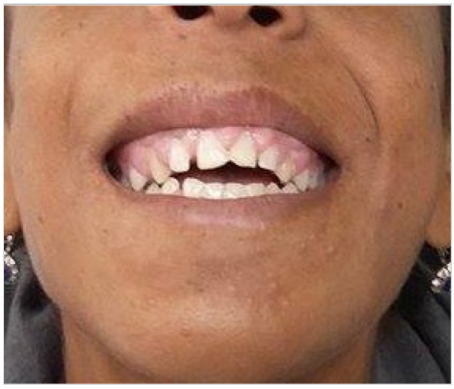

Figure 7.
Open bite and maxillary bone enlargement in the anterior area

Table 1. Results of the paraclinical tests

Paraclinical tests (reference ranges)	Case 1	Case 2	Case 3	Case 4
Hemoglobin (m 140–180 g/l; f 120–160 g/l)	112	119	79.0	96
Red blood cells (m 4.5–6.0 × 1012/l; f 3.9–5.3 × 1012/l)	3.48	3.87	2.51	3.24
Hematocrit (0.40–0.54 0.36–0.47)	0.322	0.364	0.246	0.286
Creatinine (m 74–134 µmol/l f 44-96 µmol/l)	846.0	591.0	534.0	581.0
Urea (m 3.2–8.2 mmol/l; f 2,6-7,2 mmol/l)	19.9	13.8	23.8	9.6
TPROT (60-83 g/l)	63.0	67.0	59.0	73
Albumin (35-52 g/l)	41.0	44.0	36	32
Potassium (K+) (3,5-5,6 mmol/l)	5.6	6.1	5.5	3,0
Sodium (Na+) (136-151 mmol/l)	143.0	134	143	136
Chlorine (Cl-) (96-110 mmol/l)	108.0	100.0	98	93
Iron (m 12.5–32 µmol/l f 10,7-26,7µmol/l)	20.2	27.1	10.0	7,9
Potassium total (2,2 – 2,8 mmol/l)	2.54	2.85	2.6	2,57
Phosphorus (0,77 – 1,45 mmol/l)	1.5	1.6	1.6	1,6
Parathyroid hormone (12–88 pg/ml)	3632	1144	2340	2068
Alkaline phosphatase (30-120 U/l)	2159	87	305	805

of parathyroid hormone. The alkaline phosphatase was activated and resulted in serious pathological changes in the whole skeleton [5] (full text) [6] [7] [8]. It was found that the development of secondary hyperparathyroidism is reflected most strongly in adolescents, compared to elderly patients. In young patients develop "unifying human face", while in adults observed localized "brown tumors". Most authors recommend timely transplantation in order to prevent deterioration of the quality of life of patients [14] (full text). If this is not possible, the method of choice is a partial extirpation of the parathyroid glands or *suppression* of *parathyroid hormone secretion* with calcium mimetics that bind with calcium-sensitive receptors in the parathyroid gland [15] [16]. In the maxillofacial area are discussed corrective surgery on the alveolar ridge and the extirpation of "brown tumors" [4] [5] (full text).

Conclusion

The lack of control of the level of calcium and phosphorus in the blood in patients with chronic kidney disease leads to severe bone changes and psychological changes in patients

with prolonged dialysis. The dentist must be aware of the risk of fracture of the jaw in surgical interventions due to changes in the maxillofacial area. The control of parathyroid hormone and alkaline phosphatase values prevents the development of severe changes in the bones of dialysis patients and does not decrease their quality of life.

References

[1] Hamrahian M, Pitman KT, Csongrádi É et al. Symmetrical craniofacial hypertrophy in patients with tertiary hyperparathyroidism and high-dose cinacalcet exposure. Hemodialysis international. International Symposium on Home Hemodialysis 2012 Oct;16(4):571-6

[2] Lopes ML, Albuquerque AF, Germano AR et al. Severe maxillofacial renal osteodystrophy in two patients with chronic kidney disease. Oral and maxillofacial surgery 2015 Sep;19(3):321-7

[3] Mejía Pineda A, Aguilera ML, Meléndez HJ et al. Sagliker syndrome in patients with secondary hyperparathyroidism and chronic renal failure: Case report. International journal of surgery case reports 2015;8C:127-30 (full text)

[4] Mittal S, Gupta D, Sekhri S, Goyal S. (2014) Oral Manifestations of Parathyroid Disorders and Its Dental Management. Journal of Dental and Allied Sciences 3(1).

[5] Pechalova PF, Poriazova EG Brown tumor at the jaw in patients with secondary hyperparathyroidism due to chronic renal failure. Acta medica (Hradec Kralove) / Universitas Carolina, Facultas Medica Hradec Kralove 2013;56(2):83-6 (full text)

[6] Sagliker Y, Balal M, Sagliker Ozkaynak P et al. Sagliker syndrome: uglifying human face appearance in late and severe secondary hyperparathyroidism in chronic renal failure. Seminars in nephrology 2004 Sep;24(5):449-55

[7] Sagliker Y, Acharya V, Golea O et al. Is survival enough for quality of life in Sagliker Syndrome-uglifying human face appearances in chronic kidney disease? Journal of nephrology 2008 Mar-Apr;21 Suppl 13:S134-8

[8] Sagliker Y, Acharya V, Ling Z et al. International study on Sagliker syndrome and uglifying human face appearance in severe and late secondary hyperparathyroidism in chronic kidney disease patients. Journal of renal nutrition : the official journal of the Council on Renal Nutrition of the National Kidney Foundation 2008 Jan;18(1):114-7

[9] Silva W, Almeida OP, Vargas PA, Faria KM, Lopez MAJ, Coletta RD, Silva AR. (2015) Sagliker syndrome in an end-stage renal disease patient with secondary hyperparathyroidism and localized mandible enlargement: a case report. Oral surg, orall med, oral pathol, oral radiol 120(2):e19.

[10] Yavascan O, Kose E, Alparslan C et al. Severe renal osteodystrophy in a pediatric patient with end-stage renal disease: Sagliker syndrome? Journal of renal nutrition : the official journal of the Council on Renal Nutrition of the National Kidney Foundation 2013 Jul;23(4):326-30

[11] Chang JI, Som PM, Lawson W et al. Unique imaging findings in the facial bones of renal osteodystrophy. AJNR. American journal of neuroradiology 2007 Apr;28(4):608-9 (full text)

[12] Triantafillidou K, Zouloumis L, Karakinaris G et al. Brown tumors of the jaws associated with primary or secondary hyperparathyroidism. A clinical study and review of the literature. American journal of otolaryngology 2006 Jul-Aug;27(4):281-6

[13] Fargen KM, Lin CS, Jeung JA et al. Vertebral brown tumors causing neurologic compromise. World neurosurgery 2013 Jan;79(1):208.e1-6

[14] Mohebi-Nejad A, Gatmiri SM, Abooturabi SM et al. Diagnosis and treatment of Sagliker syndrome: a case series from Iran. Iranian journal of kidney diseases 2014 Jan;8(1):76-80 (full text)

[15] Pockett RD, Cevro E, Chamberlain G et al. Assessment of resource use and costs associated with parathyroidectomy for secondary hyperparathyroidism in end stage renal disease in the UK. Journal of medical economics 2014 Mar;17(3):198-206

[16] Yang G, Zhang B, Zha XM et al. Total parathyroidectomy with autotransplantation for a rare disease derived from uremic secondary hyperparathyroidism, the uremic leontiasis ossea. Osteoporosis international : a journal established as result of cooperation between the European Foundation for Osteoporosis and the National Osteoporosis Foundation of the USA 2014 Mar;25(3):1115-21